

# Delayed Diagnosis of Left-Sided Diaphragmatic Hernia in an Elderly Adult with no History of Trauma

GOUTHAM REDDY KATUKURI<sup>1</sup>, JAGADESH MADIREDDI<sup>2</sup>, SUMIT AGARWAL<sup>3</sup>, HASHIR KAREEM<sup>4</sup>, TOM DEVASIA<sup>5</sup>

## ABSTRACT

Diaphragmatic Hernia (DH) is the herniation of abdominal contents into the thorax through a rent in the diaphragm. Acquired DH most commonly occurs following a blunt or penetrating trauma to the abdomen with former being common than the later. Very rarely DH can be spontaneous and be asymptomatic until it's very extensive. A 78-year-old presented with breathlessness and chest pain of one month duration. There was dull note to percussion and absent breath sounds in left lower zone. Auscultation revealed bowel sounds in left infra-axillary and mammary area. Electrocardiogram and laboratory data suggested acute myocardial infarction. Coronary angiogram showed a triple vessel disease. Roentgenogram was simulating pneumonic consolidation but presence of air shadows was the thing against pneumonic consolidation. CT imaging of the thorax revealed an extensive left diaphragmatic hernia with viscera and left kidney as its contents. He was initially taken up for CABG and surgery for diaphragmatic hernia was planned at a later date. This case is important for its extensive nature and for its rarity as acquired DH rarely occurs spontaneously. Chest roentgenogram must be read cautiously in all such cases to look for this entity. Auscultation for bowel sounds in the thorax is a diagnostic clue.

**Keywords:** Acquired diaphragmatic hernia, Pneumonic consolidation, Pleural effusion

## CASE REPORT

A 78-year old male, diabetic and hypertensive, came to our ED with complaints of breathlessness and chest pain of one month duration. He went to a physician at his place and was told to have hydro-pneumothorax. He was referred to a local hospital where repeated attempts of thoracocentesis did not yield any fluid. He later came to us with worsening breathlessness. Patient never had symptoms suggestive of bowel dysfunction. On arrival to our hospital he was tachypneic and tachycardia was present. Examination revealed normally placed trachea and apex but with decreased chest expansion on the left side. There was a dull note to percussion on left side with absent breath sounds on the left scapular, axillary and mammary area. Careful auscultation revealed bowel sounds in left infra-axillary area. There was no recent or remote history of trauma. Blood investigations revealed elevated serum creatinine of 2.4 mg/dl (reference range: 0.6-1.4 mg/dl), and elevated total count of 15,300 cells/ $\mu$ L (reference range: 4000-10,000 cells/ $\mu$ L) while rest all were normal. Roentgenogram at first look was simulating pneumonic consolidation but careful examination revealed gastric air shadows suggesting bowel loops [Table/Fig-1a].

Contrast enhanced Computed-Tomography imaging of chest unmasked the presence of left DH with herniation of omentum,

splenic flexure and part of transverse colon, small bowel with its mesentery and left kidney into the posterior aspect of left hemi thorax causing compressive collapse of most of left lower lobe with sparing of part of superior segment and collapse of posterior segment of left upper lobe [Table/Fig-1b,2]. CECT imaging of the chest helped us in confirming the diagnosis and the extent of the herniation.

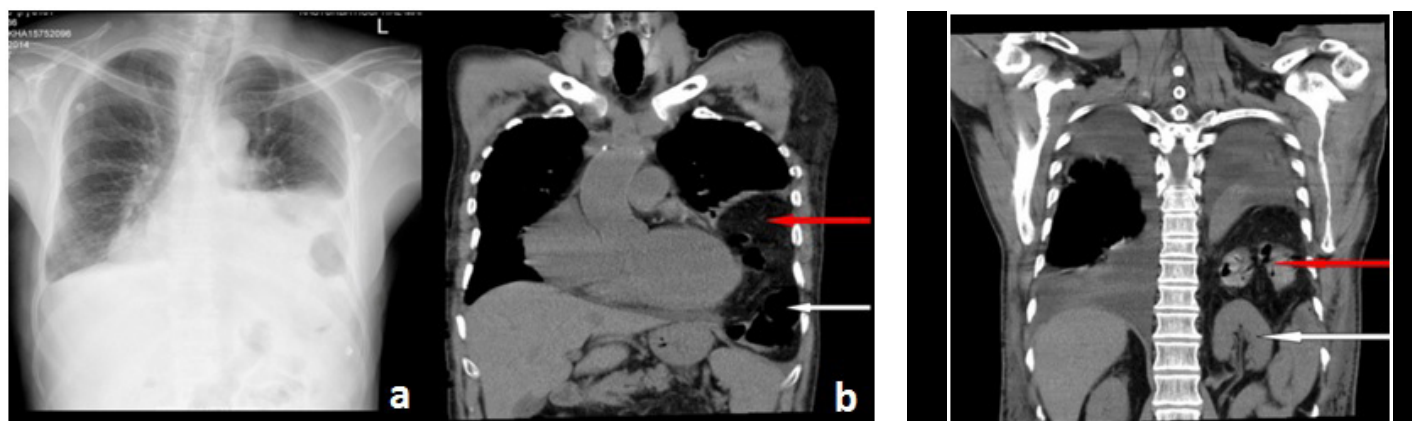
-Electrocardiogram was suggestive of anterior wall ST elevated myocardial infarction.

-Coronary angiogram revealed triple vessel disease.

He was treated IV fluids, supplemental oxygen and prophylactic antibiotic. After discussing with a general surgeon and cardiovascular surgeons, it was decided to go do CABG first. Patient underwent CABG and was discharged. Surgery for DH, by thoraco-abdominal approach, was planned at a later date. Patient was lost to follow up.

## DISCUSSION

Diaphragmatic hernia (DH) is the herniation of abdominal contents into the thorax through a rent in the diaphragm. This entity was first reported by Lazarus Riverius on postmortem examination of a 24-year-old male [1]. DH can either be congenital or acquired with former being the commonest. In subsequent paragraphs, we limit our discussion to acquired diaphragmatic hernia (ADH).



**[Table/Fig-1a]:** PA view simulating pneumonic consolidation but presence of air fluid levels point towards diaphragmatic hernia. **[Table/Fig-1b]:** CT thorax lung window coronal view: Red arrow above shows omentum and White arrow below shows large bowel. **[Table/Fig-2]:** CT thorax lung window coronal view: Red arrow (above) shows small bowel with mesentery and white arrow (below) shows kidney.

ADH mostly occurs in adults secondary to trauma. Around 3% of patients admitted to trauma department have DH [2]. Blunt trauma accounts for 75% of cases while rest to penetrating trauma. Very rarely DH occurs spontaneous with no obvious cause. However, there is always a possibility that this category of cases may be secondary to a remote trivial trauma [3] or a small congenital defect which got precipitated during physical exertion. ADH occurs 4 times more commonly in males. Its left sided predisposition is partly due to protection offered by the liver and partly because embryonic fusion defects commonly occurs in the left. Most of the cases present with symptoms of respiratory distress while few are an incidental finding. This spontaneous form may be asymptomatic for decades and becomes symptomatic in late stage when extensive. Diaphragmatic hernia resulting in acute cardiac arrest has been documented in a pregnant lady [4]. Such cases give us an insight into the severity of presentation of an undetected DH.

The disease can be suspected clinically and confirmed by meticulous examination of roentgenogram [5]. Roentgenograms must be read carefully in all cases of pneumonic consolidation and hydro-pneumothorax as both are a close masquerade to DH [6].

Treatment of ADH depends upon its presentation. Treatment in an acute setting involves resuscitation of the patient following the ACLS protocols and surgery can be reasonably delayed. When a patient presents with recent history of trauma and an ADH is diagnosed, it can be managed by laparotomy (abdominal approach). However, if hernia was diagnosed incidentally or if it's idiopathic or if it's diagnosed after few months or years of trauma, most surgeons prefer thoracic or thoraco-abdominal approach. The thoraco-abdominal approach is better to abdominal approach in

patients with a long standing DH as the herniated parts tend to adhere to intra-thoracic structures and an abdominal approach becomes difficult to tackle these adhesions. Surgical mortality is highly variable (5%-50%) depending on the concomitant injuries. Outcome following surgical correction is rewarding with recurrence only in a small number of patients.

## CONCLUSION

Our patient did not give any history of trauma in the past. The primary care physician to whom the patient had presented initially had limited access to imaging in the form of Chest Roentgenogram, without a CT. The purpose of this case report is to emphasize the importance of clinical examination and careful assessment of Roentgenogram in such patients.

## REFERENCES

- [1] Irish MS, Holm BA, Glick PL. Congenital diaphragmatic hernia. A historical review. *Clin Perinatol*. 1996;23(4):625-53.
- [2] Turhan K, Makay O, Cakan A, Samancilar O, Firat O, Icoz G, et al. Traumatic diaphragmatic rupture: look to see. *Eur J Cardiothorac Surg*. 2008;33(6):1082-85.
- [3] Arendrup HC, Jensen BS. Traumatic rupture of the diaphragm. *Surg Gynecol Obstet*. 1982;154:526-30.
- [4] Jacobs R, Honore PM, Hosseinpour N, Nieboer K, Spapen HD. Sudden cardiac arrest during pregnancy: a rare complication of acquired maternal diaphragmatic hernia. *Acta Clin Belg*. 2012;67(3).
- [5] Hanna WC, Ferri LE, Fata P, Razek T, Mulder DS. The current status of traumatic diaphragmatic injury: lessons learned from 105 patients over 13 years. *Ann Thorac Surg*. 2008;85(3):1044-48.
- [6] Oyinloye OI, Adeboye MA, Abdulkarim AA, Abdur-Rahman LO, Adesiyun OA. Traumatic diaphragmatic hernia masquerading as left-sided hydropneumothorax: a case report. *Ann Trop Paediatr*. 2010;30(1):57-60.

### PARTICULARS OF CONTRIBUTORS:

1. Junior Resident, Department of General Medicine, KMC, Manipal, India.
2. Junior Resident, Department of General Medicine, KMC, Manipal, India.
3. Senior Registrar, Department of Cardiology, KMC, Manipal, India.
4. Assistant Professor, Department of Cardiology, KMC, Manipal, India.
5. Professor, Department of Cardiology, KMC, Manipal, India.

### NAME, ADDRESS, E-MAIL ID OF THE CORRESPONDING AUTHOR:

Dr. Goutham Reddy Katukuri,  
Flat No 203, Shambavi Classic, Vidyaratna Nagar, Manipal, Udipi, Karnataka-576104, India.  
E-mail : drgouthamreddy@yahoo.com

FINANCIAL OR OTHER COMPETING INTERESTS: None.

Date of Submission: **Oct 25, 2015**  
Date of Peer Review: **Nov 28, 2015**  
Date of Acceptance: **Jan 14, 2016**  
Date of Publishing: **Apr 01, 2016**